



COMPENDIUM ON AESCULAP® LIGATION-CLIPS

TABLE OF CONTENT

I	<p>DS TITANIUM LIGATION-CLIPS</p> <p>TECHNOLOGY</p> <p>CLINICAL USE</p> <ul style="list-style-type: none"> ▪ Clip on Staple Method Reduces Clinically Relevant Pancreatic Fistula After Distal Pancreatectomy. Mizuki Ninomiya et al. ▪ Clip on Staple Method to Prevent Bile Leakage in Anatomical Liver Resection Using Stapling Devices. Mizuki Ninomiya et al. <p>PERFORMANCE</p> <ul style="list-style-type: none"> ▪ Pull-off characteristics of double-shanked compared to single-shanked ligation clips: an animal study. Schenk M et al. 	<p>PAGE</p> <p>4 - 5</p> <p>6 - 9</p> <p>10 - 11</p>
II	<p>CHALLENGER® MULTI-FIRE CLIP APPLIER</p> <p>TECHNOLOGY</p> <p>CLINICAL USE</p> <ul style="list-style-type: none"> ▪ Vascular clips versus ligatures in thyroid surgery – results of a multicenter randomized controlled trial (CLIVIT Trial). Diener MK et al. ▪ Quality of life after sympathetic surgery at the T4 ganglion for primary hyperhidrosis: clip application versus diathermic cut. Panhofer P et al. ▪ "Energy-less technique" with mini-clips for recurrent laryngeal nerve lymph node dissection in prone thoroscopic esophagectomy for esophageal cancer. Saeki H et al. 	<p>12 - 13</p> <p>14 - 19</p>
III	<p>DS APPENDECTOMY-CLIP</p> <p>TECHNOLOGY</p> <p>COST EFFICIENCY</p> <p>CLINICAL USE</p> <ul style="list-style-type: none"> ▪ The TICAP-Study (titanium clips for appendicular stump closure): A prospective multicentre observational study on appendicular stump closure with an innovative titanium clip. Rickert A et al. ▪ Appendix stump closure with titanium clips in laparoscopic appendectomy. Rickert A et al. ▪ Appendectomies – Indications and a comparison of the various treatment methods. Eisenberger CF et al. <p>PERFORMANCE</p> <ul style="list-style-type: none"> ▪ Managing the appendicular stump during a laparoscopic appendectomy. Partecke LI et al. 	<p>20 - 21</p> <p>22 - 27</p> <p>28 - 37</p> <p>38 - 43</p>

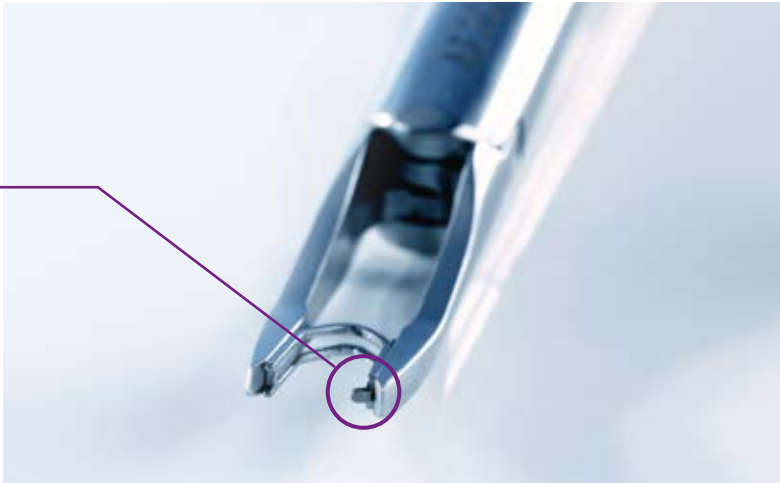DS TITANIUM LIGATION-CLIPS TECHNOLOGY



DS Titanium Ligation-Clip
without latch



DS Titanium Ligation-Clip
with latch (z)



A latch at the distal end of the clip additionally
prevents the clip from slipping.

Innovative, reliable, convenient

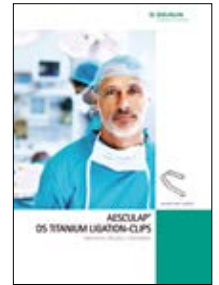
- **INNOVATIVE:** This system is innovative and unique in the segment of Titanium Ligation-Clips
- **RELIABLE:** The DS-Clip provides a firm hold on the clipped structure
- **CONVENIENT:** The system is easy to use. It does not require an adaption of the order of operation

Double-shank Clip

- The DS-Clip has a clip shape with parallel arranged bars with a gap between which compresses the tissue. They stabilize the clip against axial dislodgement
- The clip closes from the tip
- A diamond-shaped inner clip profile leads to an enlarged contact surface with the tissue
- The clip is made of the material pure titanium

Closing behavior of the clip

The special closing characteristic of the clip allows a repositioning of the clip and reduces the risk of tissue slippage out of the clip



For more information
see brochure no. C88011

DS TITANIUM LIGATION-CLIPS

CLINICAL USE

ABSTRACT

CLIP ON STAPLE METHOD REDUCES CLINICALLY RELEVANT PANCREATIC FISTULA AFTER DISTAL PANCREATECTOMY.

Ninomiya M, Tomino T, Matono R, Motomura T, Uchiyama H, Nishizaki T

Anticancer Res. 2019 Dec;39(12):6799-6806.

BACKGROUND/AIM:

In order to overcome postoperative pancreatic fistula (POPF) after distal pancreatectomy (DP), we have developed a new simple technique-Clip on Staple method.

PATIENTS AND METHODS:

In Clip on Staple method, pancreatic parenchyma was divided using a stapling device with a stepped-height staple design to make linear compression line, and thereafter, the full length of the staple line was reinforced by multiple clips. Clinical outcomes were retrospectively compared between Clip on Staple group (n=23) and Non-Clip group (n=38).

RESULTS:

The incidence of clinically relevant POPF (CR-POPF) was significantly lower in the Clip on Staple group than in the Non-Clip group (4.3 and 36.8%, $p=0.005$). Multivariate logistic regression analysis revealed that only Clip on Staple method was an independent predictive factor of a decrease in the occurrence of CR-POPF.

CONCLUSION:

The Clip on Staple method, a simple and easily applicable technique even in laparoscopic surgery, significantly reduced the occurrence of CR-POPF among patients undergoing DP.



← <https://pubmed.ncbi.nlm.nih.gov/31810945/>

MAJOR STATEMENTS

- The Clip on Staple method is a simple and easily applicable technique to reduce clinically relevant postoperative pancreatic fistula (CR-POPF).
- In the group of patients where the Clip on Staple method was used, with the DS-Clips as clipping device, the incidence of clinically relevant postoperative pancreatic fistula (CR-POPF) was significantly lower than in the non-clip group.
- Laparoscopic surgery was performed in 91% of cases in the Clip on Staple group, compared to 61% in the non-clip group, resulting in a significantly longer operative time.
- Within 90 days, there was no reoperation or mortality in both groups.
- In the Clip on Staple group, not a single patient required suture reinforcement, compared to 8 of 38 patients in the non-clip group.
- The incidence of severe complications (grade 3a or more) was significantly lower in the group of patients where the Clip on Staple method was used compared to the non-clip group. In fact, no patient in the Clip on Staple group developed a severe complication.
- The only independent variable predicting factor for a decrease in occurrence rate of CR-POPF in multivariate analysis was the application of the Clip on Staple method.

DS TITANIUM LIGATION-CLIPS CLINICAL USE

ABSTRACT

CLIP ON STAPLE METHOD TO PREVENT BILE LEAKAGE IN ANATOMICAL LIVER RESECTION USING STAPLING DEVICES.

Ninomiya M, Tomino T, Matono R, Nishizaki T

Anticancer Res. 2020 Jan;40(1):401-404.

BACKGROUND/AIM:

Bile leakage after liver surgery is still a problem to be solved. Here, we introduce a simple new technique, the Clip on Staple method, a preventive measure for bile leakage after anatomical liver resection using a stapling device.

PATIENTS AND METHODS:

Before liver parenchymal transection, the roots of Glissonian pedicles for target segments were dissected and divided using the Endo-GIA™ Tri-Staple™ Curved Tip. After the parenchymal transection was completed, the full length of the stapled stump was reinforced by multiple clips. The DS Titanium Ligation Clip was used as the clipping device.

RESULTS:

Twenty patients underwent this technique during anatomical liver resections with stapling devices. No patient developed postoperative bile leakage of any grade. There was no reoperation or readmission within 90 days.

CONCLUSION:

The Clip on Staple method is simple and offers a preventive effect for postoperative bile leakage after anatomical liver resection using stapling devices.



← <https://pubmed.ncbi.nlm.nih.gov/31892593/>

MAJOR STATEMENTS

- The Clip on Staple method contributes to the prevention of stump widening following improper staple formation and subsequent postoperative bile leakage after anatomical liver resection using stapling devices.
- Of the treated 20 patients (of which 19 underwent laparoscopic surgery), none developed postoperative bile leakage of any grade. Also, no reoperation or readmission occurred within 90 days.
- DS-Clips were used for reinforcement of the parenchymal stump after liver parenchymal transection.
- In laparoscopic anatomical liver resection using stapling devices, the Clip on Staple method is a simple alternative to suture reinforcement of the stapled stump.

DS TITANIUM LIGATION-CLIPS PERFORMANCE

ABSTRACT

PULL-OFF CHARACTERISTICS OF DOUBLE-SHANKED COMPARED TO SINGLE-SHANKED LIGATION CLIPS: AN ANIMAL STUDY.

Schenk M, Müller G, Greiner TO, Fahrner C, Königsrainer A, Thiel C

Innov Surg Sci., 1.1 (2016): 41-46.

BACKGROUND:

The use of surgical ligation clips is considered as the gold standard for the closure of vessels, particularly in laparoscopic surgery. The safety of clips is mainly achieved by the deep indentation of the metal bar with a high retention force. A novel double-shanked (DS) titanium clip was compared to two single-shanked clips with respect to axial and radial pull-off forces.

METHODS:

In a porcine model (8 animals, 51 ± 1 kg), arteries were prepared immediately after euthanasia, assigned to either a medium (2–4 mm; n=120) or a medium-large (3.5–7 mm; n=120) clip size group, and clipped with the appropriate clip size. After dissection, axial and radial pull-off forces were measured.

RESULTS:

The axial pull-off force of the DS-Clip was higher than one single-shanked clip and comparable to the other single-shanked clip, and overall was linearly correlated to the cross-sectional area of the clip. The radial pull-off force of the DS-Clip was significantly higher than both single-shanked clips and, for the single-shanked clips, was correlated to the total clip thickness. The variation of radial pull-off force was lower for the DS-Clip due to a defined catch in the clip applicator.

CONCLUSION:

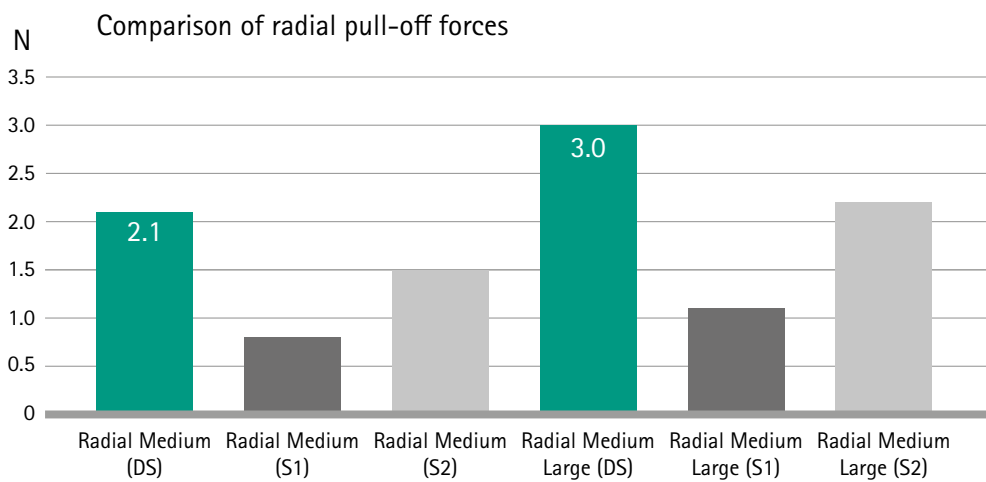
The radial pull-off force was lower than the axial pull-off force in total and therefore appears to be the critical point of dislocation. Due to the higher total holding mass, the DS-Clip provided a clear advantage in this regard and might therefore decrease the dislocation rate. The catch in the applicator increases the reproducibility in clip placement.



← <http://dx.doi.org/10.1515/iss-2016-0003>

MAJOR STATEMENTS

- The investigated DS-Clips feature a clear advantage over regular "V-shaped" clips.
- DS-Clips are superior regarding the radial pull-off force, when compared to single-shanked clips. Radial kind of shear stress can be deemed critical for clip dislocation because the radial pull-off force is considerably smaller than the axial pull-off force.



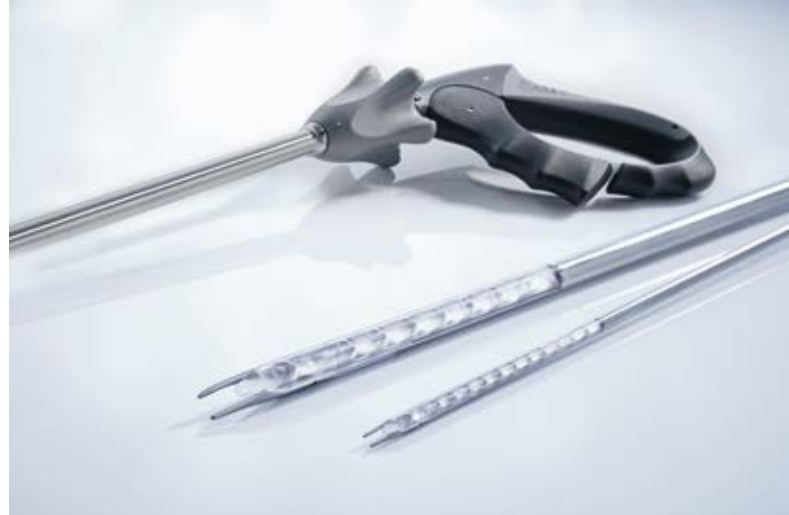Source: Pull-off characteristics of double-shanked compared to single-shanked ligation clips: an animal study; Schenk et al.

- The radial pull-off forces of the DS-Clip show a lower variation coefficient when compared to single-shanked clips.
- Referring to safety, availability, speed and costs, ligation clips remain the gold standard for the closure of vessels and hollow organs.

CHALLENGER® MULTI-FIRE CLIP APPLIER TECHNOLOGY

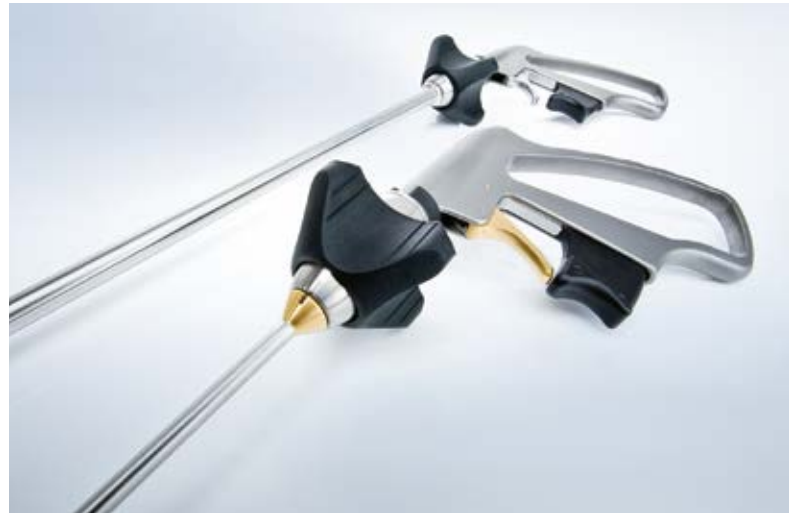AESCULAP® Challenger® Ti-P Pneumatic Reusable Multi-Fire Clip Applier

- Modular design simplifies disassembly, cleaning, maintenance and sterile preparation
- Innovative technology – pneumatic clip loading
- Reliable vessel occlusion
- Reusable system – reusable applier and single use clip cartridge
- One system with different shafts





AESCULAP® Challenger® Ti Reusable Multi-Fire Clip Applier

- Separate functional elements for clip loading and clip closure




Clip Profile

A diamond-shaped inner clip profile provides an enlarged contact surface



For more information
see brochure no. C62311



For more information
see brochure no. C46111

Closing behavior of the clip

The special closing characteristic of the clip allows a repositioning of the clip and reduces the risk of tissue slippage out of the clip



Clip cartridges for 5 mm (SM) and 10 mm (ML) clip applicators



Challenger® Ti-P. Sterile package of clip cartridge
(clip cartridge + CO2 cylinder), last clip color-coded



Challenger® Ti: Sterile package of clip
cartridge, last clip color-coded

CHALLENGER[®] MULTI-FIRE CLIP APPLIER

CLINICAL USE

ABSTRACT

VASCULAR CLIPS VERSUS LIGATURES IN THYROID SURGERY-RESULTS OF A MULTICENTER RANDOMIZED CONTROLLED TRIAL (CLIVIT TRIAL).

Diener MK, Seiler CM, von Frankenberg M, Rendel K, Schüle S, Maschuw K, Riedl S, Rückert JC, Eckmann C, Scharlau U, Ulrich A, Bruckner T, Knaebel HP, Rothmund M, Büchler MW; CLIVIT Study Group.

Langenbecks Arch Surg. 2012 Oct;397(7):1117-26.

BACKGROUND:

New techniques using vascular clips or ultrasonically activated shears have been suggested to shorten operation time without compromising safety. The objective of the CLIVIT Trial was to compare ligatures with vascular clips for hemostasis in elective benign thyroid surgery.

METHODS:

This multicenter, randomized, controlled, parallel group superiority trial was conducted in 13 German surgical centers. Patients scheduled for at least subtotal resection bilaterally were intraoperatively randomized. The primary endpoint was resection time. Secondary endpoints were the amount of postoperative bleeding, reoperation due to bleeding, wound infection, temporary (reversal within 12 months) and permanent (over 1 year) recurrent laryngeal nerve (RLN) paralysis, length of hospital stay, and safety.

REGISTRATION:

ISRCTN 96901396.

RESULTS:

Two hundred fifty patients were treated with ligatures and 241 with vascular clips. No differences in patients' baseline and surgical characteristics were observed. No difference was detected for mean resection time (clip 63.5 min \pm 29.6, ligature 66.1 min \pm 29.3, $P=0.258$). Postoperative bleeding (mean 86 ml \pm 93), reoperation due to bleeding (clips 4, ligature 2), wound infections (clips 4, ligature 4), postoperative hospital stay (mean 3.0 \pm 1.9), and safety data also did not vary significantly. The rates of temporary and permanent RLN paralysis were 6.9 % (34/491) and 2.9 % (14/491), respectively. Not using a surgical drain (123 patients) was not associated with a higher rate of complications.

CONCLUSION:

Vascular clips did not reduce the resection time. However, a 2.9 % rate of permanent RLN paralysis is of concern. Drains in elective surgery may be of no benefit.



← <https://www.ncbi.nlm.nih.gov/pubmed/22729718>

MAJOR STATEMENTS

- The CLIVIT study shows the safety of vascular clips in comparison to the conventional ligation with sutures.
- No significant differences were observed for postoperative bleeding, reoperation due to bleeding, wound infections, postoperative hospital stay and rates of temporal and permanent recurrent laryngeal nerve paralysis.
- The application of vascular clips is simpler in comparison to ligatures and they do not require further equipment such as power supplies.
- Methodically, in the clip group, vessels were occluded by application of one clip close to the thyroid capsule and two clips distal to the thyroid.
- Reductions in the mean resection time were observed, although not significant. In addition, differences in the operation time are linked to the surgeon's experience.

CHALLENGER[®] MULTI-FIRE CLIP APPLIER

CLINICAL USE

ABSTRACT

QUALITY OF LIFE AFTER SYMPATHETIC SURGERY AT THE T4 GANGLION FOR PRIMARY HYPERHIDROSIS: CLIP APPLICATION VERSUS DIATHERMIC CUT.

Panhofer P, Ringhofer C, Gleiss A, Jakesz R, Prager M, Bischof G, Neumayer C

Int J Surg. 2014 Dec;12(12):1478-83.

INTRODUCTION:

Limited procedures at the T4 ganglion show low rates of compensatory sweating (CS). The aim of the study was to compare endoscopic sympathetic block (ESB) via clip application with endothoracic sympathicotomy (ETS) via diathermy with special regard on patients' quality of life (QoL).

PATIENTS AND METHODS:

Treatment success, side effects and patient satisfaction were evaluated in a prospectively gathered database of a tertiary-care referral hospital. Two disease-specific QoL questionnaires were used (Keller, Milanez de Campos).

RESULTS:

406 operations were performed in 205 patients (ESB4 N = 114, ETS4 N = 91) with a median follow-up of 12 months. Both procedures improved QoL significantly ($P < 0.001$) and the degree of improvement was equal in both groups. Palmar and axillary HH were ameliorated after both procedures ($P < 0.001$). Accordingly, plantar HH decreased after ESB4 ($P = 0.002$), while remaining unaltered after ETS4. Nineteen patients (9.3%) reported CS and 10 patients (4.9%) judged it as „disturbing“. Nine of the latter belonged to the ETS4 group compared to one ESB patient ($P = 0.015$). Patients developed higher rates of plantar CS after ETS4 compared to ESB4 ($P = 0.006$). Five patients (2.4%) from both cohorts reported persistence of axillary HH. Recurrence of axillary symptoms was found in 5 ESB4 patients. Satisfaction rates did not differ significantly.

CONCLUSION:

Patients' QoL and satisfaction rates are similar in both treatment groups for upper limb HH. Outcome and recurrence rates speak in the favor of ETS4, severity of CS and potential reversibility argue for ESB4.



← <https://www.ncbi.nlm.nih.gov/pubmed/25463770>

MAJOR STATEMENTS

- Compensatory sweating rates in the cited study were in both groups lower in comparison to the existing literature.
- Endoscopic sympathetic blocks at T4 via clip application as well as endoscopic thoracic sympathectomies at T4 via diathermy improved patients' quality of life significantly.
- Differences in outcome, recurrence rates, severity of compensatory sweating and potential reversibility exist between the treatment groups.
- In both treatment groups, the patients' quality of life and satisfaction rates did not differ significantly for upper limb severe primary hyperhidrosis.
- The clip group has been treated, using the Challenger® Ti.

CHALLENGER[®] MULTI-FIRE CLIP APPLIER

CLINICAL USE

ABSTRACT

"ENERGY-LESS TECHNIQUE" WITH MINI-CLIPS FOR RECURRENT LARYNGEAL NERVE LYMPH NODE DISSECTION IN PRONE THORACOSCOPIC ESOPHAGECTOMY FOR ESOPHAGEAL CANCER.

Saeki H, Nakashima Y, Hirose K, Sasaki S, Jogo T, Taniguchi D, Edahiro K, Korehisa S, Kudou K, Nakanishi R, Kubo N, Ando K, Kabashima A, Oki E, Maehara Y

Am J Surg. 2017 Oct 23. pii: S0002-9610(17)31290-4.

BACKGROUND:

Meticulous recurrent laryngeal nerve (RLN) lymph node dissection in thoracoscopic esophagectomy for esophageal cancer often results in RLN paralysis.

METHODS:

We had attempted to simply cut the vessels around RLN sharply with scissors without using energy device in order to prevent RLN paralysis. However, these procedures often result in minor bleeding. Since we introduced the use of mini-clips for hemostasis before cutting the vessels with scissors, we herein compared the surgical results between before and after the introduction of use of mini-clips.

RESULTS:

With regard to RLN paralysis, the incidence was 24.0% in the before group; this incidence went down to 5.1% in the after group ($P = 0.0259$). Moreover, length of hospital stay after surgery was significantly shortened, from 36.1 days to 22.0 days, after the introduction of energy-less techniques with mini-clips ($P = 0.0075$).

CONCLUSION:

Our data demonstrated that this technique contributed to prevent RLN paralysis and to shorten the patient's length of hospital stay.



← <https://www.ncbi.nlm.nih.gov/pubmed/29089097>

MAJOR STATEMENTS

- Energy-less-procedures are considered to be more advantageous in terms of preventing laryngeal nerve paralysis when performing lymph node dissection along the recurrent laryngeal nerve (RLN).
- The study was comparing cutting vessels without using energy devices versus the usage of Challenger® Ti clips.
- The treatment with clips contributed to a dry surgical field, decreased incidence of RLN paralysis and a significantly shorter hospital stay.
- The authors believe that the use of clips had a big influence on the improved surgical results.

DS APPENDECTOMY CLIP TECHNOLOGY



DS (Double-shank) Appendectomy-Clip

Innovative, reliable, convenient, cost effective

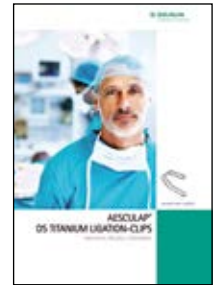
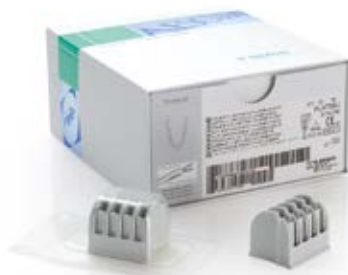- **INNOVATIVE:** This system is innovative and unique in the segment of Titanium Ligation-Clips
- **RELIABLE:** The DS-Clip provides a firm hold on the appendix
- **CONVENIENT:** The system is easy to use. It does not require an adaption of the order of operation
- **COST EFFECTIVE:** A cost-effective system due to reusable clip appliers

Double-shank Clip

- The DS-Clip has a clip shape with parallel arranged bars with a gap between which compresses the tissue. They stabilize the clip against axial dislodgement
- A latch at the distal end of the clip additionally prevents the clip from slipping
- The clip closes from the tip
- A diamond-shaped inner clip profile leads to an enlarged contact surface with the tissue
- The clip is made of the material pure titanium

Closing behavior of the clip

The special closing characteristic of the clip allows a repositioning of the clip and reduces the risk of tissue slippage out of the clip



For more information
see brochure no. C64311

DS APPENDECTOMY-CLIP

COST EFFICIENCY

COST EFFICIENCY IN APPENDECTOMIES

LINEAR STAPLER VS. TITANIUM CLIPS

Appendectomies belong to the most frequent surgical procedures in Germany in 2017 (1). In Germany about 135,000 appendectomies are performed every year (2). However, the debate about the best closure technique for the appendicular stump, is still ongoing. Hence, the aim of this paper is to briefly outline medical advantages and disadvantages of different closure techniques. Furthermore, this paper compares the economic aspects of two of these methods: linear staplers, and titanium clips.

COMPARISON OF ENDOLOOPS, LINEAR STAPLERS, AND CLIPS:

Endoloops, linear staplers, and clips are commonly used for closure of the appendicular stump. Although these methods have varying disadvantages, a recent study (3) showed them to be equally safe. Endoloops were shown to require a longer operation time, more training, and more experienced users in comparison to linear staplers and clips. Additionally, when using endoloops, a longer appendix stump remains. An advantage of the endoloops is that it is applicable for nearly all diameters of the appendix, and especially in case of mild inflammation (4). Linear staplers were found to incur a longer operation time than the clip (3) and leave metal staples in the abdominal cavity (5,6). Nevertheless, they are easy to use and allow safe closure even for an inflamed appendix stump (4). Currently, there are polymer and titanium clips available. Both clips are technically limited as they might not be used for severely inflamed appendices or a too large diameter of the appendicular stump. However, the Aesculap DS Appendectomy-Clip, a titanium clip which was used in the study by Rickert et al., safely closed appendices with a stump of up to 20 mm and could hence be applied in about 80% of laparoscopic appendectomies (3). The DS-Clip received high satisfaction scores by surgeons (4). Overall, it can be said that no significant differences in clinical outcome between the closure techniques discussed above could be found. For all of them, secure closure of the appendicular stump is highly likely. Hence, the decision of which method to use is at the discretion of the operating surgeon.

ECONOMIC EFFECTIVENESS: DS-CLIP VS LINEAR STAPLER:

There is one factor that has not been taken into account: the economic effectiveness. As linear staplers are currently most frequently used in laparoscopic appendectomies in Germany (7), they will be compared to the Aesculap DS Appendectomy-Clip regarding economic effectiveness as follows. When merely looking at the costs of the Aesculap DS Appendectomy-Clip in comparison to linear staplers, the clip, with around € 80 for a set of four, is considerably cheaper than the stapler, which costs about €200 including one charge of staples. An article describes material costs of €280 for one stapler and one charge of staples (7). However, in this paper the costs of the stapler will be calculated with the lower assumption of €200. The following example of the German reimbursement system, the DRG (Diagnosis Related Groups) system, shows the impact of the closure technique to the overall process costs of a laparoscopic appendectomy.

DRGS FOR APPENDECTOMIES:

There are six different DRGs that include appendectomies. G23C is the most common DRG for appendectomies, documented the most (56.16% of cases), and is used in this example. G23C is a code used for classification of procedures and includes appendectomies where the diagnosis of peritonitis is negative, and the patient is older than 13 years (8).

For the hospital, the costs of performing a laparoscopic appendectomy are €2,536.48 on average (table 1). A significant aspect is that only €218.06 are planned as direct costs in the OR for necessary individual items. In comparison to the other DRGs for appendectomies, it shows that the direct costs in the OR are on an average. Nevertheless, savings on these costs are of specific importance in appendectomies since an increasing severity leads to a decreasing direct cost budget in the OR. In case of the appendectomy, these items would include either the stapler or the clip, a retrieval bag, suture material, and other items. For example, when using a stapler for the appendectomy, there is an insufficient coverage of costs because already the use of a stapler costs around €200. On the contrary, this would not be the case for the Aesculap DS Appendectomy-Clip as it costs only €80 (as shown in table 2). (9)

REVENUE FOR HOSPITALS:

When making the entire calculation for the costs using a linear stapler compared to the DS Appendectomy-Clip, and taking into account what the hospital receives for a G23C DRG, a greater return for a laparoscopic appendectomy using the DS-Clip becomes evident. The calculated return for the DRG for every surgery is €414.19 as the reimbursement is €2,950.67 (10) and the actual costs on average are €2,536.48. When using a stapler, hospitals have a deficient cover of direct costs in the OR, which means they have a lower return amounting to €377.25 for every surgery. However, when using the Aesculap DS Appendectomy-Clip the return increases to €497.25 for every surgery. When projecting this for a larger German institution with 350 appendectomies every year, this will result in saving €40,000 every year (table 3). All calculations in this paper are based on the DRG report browser (9).

CONCLUSION:

From this paper, we can conclude that endoloops, linear staplers, and clips are clinically not significantly different. It rather seems that the method of choice depends on the surgeons' preferences and expertise. From the economic perspective, a difference between the linear stapler and the Aesculap DS Appendectomy-Clip is apparent. When simply comparing the costs of the two devices, the Appendectomy-Clip is approx. €120 cheaper than a stapler. When using Germany as an example, and taking into account the DRG system for reimbursement, using the Appendectomy-Clip instead of a linear stapler would save around €40,000 every year in a medical centre in which 350 appendectomies are performed. This shows that the Aesculap DS Appendectomy-Clip has an outstanding cost effectiveness while offering the same reliability as existing options.

DS APPENDECTOMY-CLIP

COST EFFICIENCY

REFERENCES / SOURCE INFORMATION

- 1 Gesundheitsberichterstattung des Bundes. Die 50 häufigsten Operationen der vollstationären Patientinnen und Patienten in Krankenhäusern (Rang, Anzahl, Anteil in Prozent). [Internet] www.gbe-bund.de. 2018 Jan 15 [cited 15 January 2019] URL: http://www.gbe-bund.de/oowa921-install/servlet/oowa/aw92/dboowasys921.xwdevkit/xwd_init?gbe.isgbetol/xs_start_neu/etp_aid=3&etp_aid=10034239&nummer=666&etp_sprache=D&etp_indsp=-&etp_aid=75240984
- 2 Sahn M, Koch A, Schmidt U, Wolff S, Pross M, Gastinger I et al. Akute Appendizitis - Klinische Versorgungsforschung zur aktuellen chirurgischen Therapie [Acute appendicitis - clinical health-service research on the current surgical therapy]. Zentralblatt für Chirurgie - Zeitschrift für Allgemeine, Viszeral-, Thorax- und Gefäßchirurgie. 2013;138(03):270-277.
- 3 Rickert A, Krüger C, Runkel N, Kuthe A, Königer J, Jansen-Winkeln B et al. The TICAP-Study (titanium clips for appendicular stump closure): A prospective multicentre observational study on appendicular stump closure with an innovative titanium clip. BMC Surgery. 2015;15(85).
- 4 Partecke L, Diedrich S. CME-Artikel: Die Appendixstumpfvorsorgung bei der laparoskopischen Appendektomie [Managing the appendicular stump during a laparoscopic appendectomy]. Passion Chirurgie [Internet]. 2013 [cited 2 March 2018];04. Available from: <https://www.bdc.de/die-appendixstumpfvorsorgung-bei-der-laparoskopischen-appendektomie/>
- 5 Kazemier G, in't Hof K, Saad S, Bonjer H, Sauerland S. Securing the appendiceal stump in laparoscopic appendectomy: evidence for routine stapling?. Surgical Endoscopy. 2006;20(9):1473-1476.
- 6 Chepla K, Wilhelm S. Delayed Mechanical Small Bowel Obstruction Caused by Retained, Free, Intraperitoneal Staple After Laparoscopic Appendectomy. Surgical Laparoscopy, Endoscopy & Percutaneous Techniques. 2011;21(1):e19-e20.
- 7 Mehdorn M, Schürmann O, Mehdorn H, Gockel I. Intended cost reduction in laparoscopic appendectomy by introducing the endoloop: a single center experience. BMC Surgery. 2017;17(1).
- 8 InEK. Fallpauschalen-Katalog 2018, InEK GmbH [Internet]. G-drg.de. 2018 [cited 21 February 2018]. Available from: http://www.g-drg.de/G-DRG-System_2018/Fallpauschalen-Katalog/Fallpauschalen-Katalog_2018
- 9 InEK. G-DRG-Report-Browser 2018, InEK GmbH [Internet]. G-drg.de. 2018 [cited 02 March 2018]. Available from: http://www.g-drg.de/Datenbrowser_und_Begleitforschung/G-DRG-Report-Browser/G-DRG-Report-Browser_2018
- 10 Webgrouper [Internet]. Drg.uni-muenster.de. 2018 [cited 2 March 2018]. Available from: http://drg.uni-muenster.de/index.php?option=com_webgrouper&view=webgrouper&Itemid=112

TABLE 1: Calculation of costs for performing a laparoscopic appendectomy (9)

Costs	Personnel Costs			Material Costs						Personnel and Material Costs		Total
	Medical Service	Nursing Service	Medical Technical Service	Pharmaceuticals		Implant/Transplant	Other Medical Supplies			Medical Infra-structure	Non-med. Infra-structure	
	1	2	3	4a	4b	5	6a	6b	6c	7	8	
Normal Ward	€ 214.76	€ 295.68	€ 14.53	€ 21.22	€ 0.76	€ 0.00	€ 28.44	€ 0.49	€ 1.87	€ 101.22	€ 297.27	€ 976.24
Intensive Ward	€ 2.33	€ 3.99	€ 0.10	€ 0.35	€ 0.03	€ 0.00	€ 0.56	€ 0.00	€ 0.00	€ 0.84	€ 2.30	€ 10.50
Operation Area	€ 194.01	€ 0.00	€ 173.11	€ 5.47	€ 0.32	€ 1.71	€ 96.54	€ 218.06	€ 1.47	€ 97.26	€ 124.99	€ 912.94
Anesthesia	€ 160.68	€ 0.00	€ 108.69	€ 8.61	€ 0.92	€ 0.00	€ 28.80	€ 0.38	€ 0.39	€ 21.23	€ 45.24	€ 374.94
Cardiological Diagnostics/Therapy	€ 0.00	€ 0.00	€ 0.00	€ 0.00	€ 0.00	€ 0.00	€ 0.00	€ 0.02	€ 0.03	€ 0.00	€ 0.00	€ 0.05
Endoscopic Diagnostics/Therapy	€ 1.82	€ 0.00	€ 2.08	€ 0.07	€ 0.00	€ 0.00	€ 0.76	€ 0.14	€ 0.01	€ 0.91	€ 1.56	€ 7.35
Radiology	€ 6.13	€ 0.00	€ 6.70	€ 0.07	€ 0.04	€ 0.00	€ 1.09	€ 0.54	€ 4.68	€ 2.56	€ 4.19	€ 26.00
Laboratories	€ 5.50	€ 0.00	€ 22.80	€ 0.68	€ 0.06	€ 0.00	€ 16.28	€ 1.11	€ 24.92	€ 2.88	€ 9.84	€ 84.07
Diagnostic Reports	€ 9.09	€ 0.06	€ 5.24	€ 0.18	€ 0.00	€ 0.00	€ 0.94	€ 0.00	€ 0.03	€ 1.55	€ 3.96	€ 21.05
Therapeutic Procedures	€ 0.29	€ 0.04	€ 1.52	€ 0.01	€ 0.00	€ 0.00	€ 0.06	€ 0.00	€ 0.26	€ 0.08	€ 0.43	€ 2.69
Patient Admission	€ 38.43	€ 8.29	€ 37.21	€ 1.33	€ 0.06	€ 0.00	€ 5.20	€ 0.03	€ 0.02	€ 6.05	€ 24.03	€ 120.65
Total	€ 633.04	€ 308.06	€ 371.98	€ 37.99	€ 2.19	€ 1.71	€ 178.67	€ 220.77	€ 33.68	€ 234.58	€ 513.81	€ 2,536.48

[4a and 6a represent costs that are independent of the duration of the hospital stay; items that are used often and that are not billed separately. 4b and 6b include expensive, individually counted items]

DS APPENDECTOMY-CLIP COST EFFICIENCY

TABLE 2: Cost calculation for direct costs in the OR for individually counted items

	Costs		Costs
Scheduled costs in the operation area using a linear stapler	€ 218.06	Scheduled costs in the operation area using the DS Appendectomy-Clip	€ 218.06
- Linear Stapler	€ -200	- DS Appendectomy-Clip	€ -80
- Retrieval bag	€ -20	- Retrieval Bag	€ -20
- Suture material	€ -15	- Suture material	€ -15
- Other	€ -20	- Other	€ -20
Deficient cover/surgery due to "direct costs in the OR"	€ -36.94	Surplus cover/surgery due to "direct costs in the OR"	€ 83.06

TABLE 3: Case study for returns when using a linear stapler or the DS Appendectomy-Clip

Return when using a linear stapler (approx. € 200 / treatment)

Calc. return of the DRG/ surgery	€ 414.19
- Deficient cover/surgery due to "direct costs in the OR"	€ -36.94
= Expected remaining return/ surgery	€ 377.25
* Average appendectomies p.a./institution	*350
= Expected max. return for 350 appendectomies p.a.	€ 132,037.50

Return when using the DS Appendectomy-Clip (approx. € 80 / treatment)

Calc. return of the DRG/ surgery	€ 414.19
+ Surplus cover/surgery due to "direct costs in the OR"	€ +83.06
= Expected remaining return/ surgery	€ 497.25
* Average appendectomies p.a./institution	*350
= Effective return for 350 appendectomies p.a.	€ 174,037.50

- For the major closure techniques (Endoloops, linear staplers and clips), secure closure of the appendicular stump is highly likely. Therefore, the operating surgeon decides which method he prefers for the individual patient.
- Taking the German DRG-System into account, it shows that only 218.06 EUR are planned as direct costs in the OR (retrieval bag and others in addition to linear staplers or clips).
- Under an assumed hospital price setting, the DS Appendectomy-Clip is 120 EUR cheaper than a linear stapler per single case.
- Calculating this for a larger institution performing 350 appendectomies per year, this amounts to a cost saving of about 40,000 EUR annually.

DS APPENDECTOMY-CLIP CLINICAL USE

ABSTRACT

THE TICAP-STUDY (TITANIUM CLIPS FOR APPENDICULAR STUMP CLOSURE): A PROSPECTIVE MULTICENTRE OBSERVATIONAL STUDY ON APPENDICULAR STUMP CLOSURE WITH AN INNOVATIVE TITANIUM CLIP.

Rickert A, Krüger CM, Runkel N, Kuthe A, Königer J, Jansen-Winkel B, Gutt CN, Marcus DR, Hoey B, Wente MN, Kienle P

BMC Surg. 2015 Jul 17;15:85. doi: 10.1186/s12893-015-0068-3.

BACKGROUND:

To evaluate the effectiveness and safety of the DS Titanium Ligation Clip for appendicular stump closure in laparoscopic appendectomy.

METHODS:

Overall, 502 patients undergoing laparoscopic appendectomy were recruited for this observational multicentre study in nine study centres between October 2011 and July 2013. The clip was finally applied in 390 patients. Primary outcome variables were feasibility of the clip, intra-abdominal surgical site (abscesses, stump leakages) and superficial wound infections. Patients were followed 30 days after surgery.

RESULTS:

The clip was applicable in nearly 80 % of patients. Reasons for not applying the clip were mainly an inflamed caecum or a too large diameter of the appendix base. Superficial wound infections were found in nine (2.31 %), intra-abdominal abscesses in five (1.28 %), appendicular stump leak in one (0.26 %), and other adverse events in 22 (5.64 %) patients. In total, 12 (3.08 %) patients were re-admitted to hospital for treatment. Seven re-admissions were surgery-related; ten (2.56 %) patients had to be re-operated. One patient died during the course of the study due to persisting peritonitis (mortality 0.26 %).

CONCLUSION:

The results suggest that the DS Titanium Ligation Clip is a safe and effective option in securing the appendicular stump in laparoscopic appendectomy. The complication rates found with the use of the DS-Clip are comparable to the rates in the literature when other methods are used.

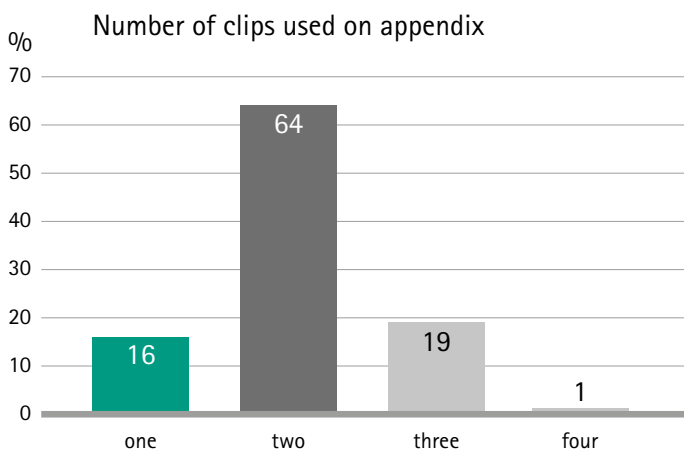
TRIAL REGISTRATION:

NCT01734837.



← <https://www.ncbi.nlm.nih.gov/pubmed/26185103>

- Hospitals with different number of operations, supply levels as well as experience of surgeons were contributing to the TICAP-Study.
- There are existing studies, summarizing the use of Hem-o-lok clips for appendix bases up to 10mm and endoloops up to 15mm. In comparison to that, the DS Appendectomy-Clip in the TICAP-Study was used for stump diameters up to 20 mm.
- The DS Appendectomy-Clip was used for the ligation of the appendix in approx. 80% of the cases.
- The final decision about the number of clips used is taken by the operating surgeon, whereat the application of one clip on the stump was deemed as adequate.



- There is a comparative cost ratio of 80€ for a cartridge of four DS Appendectomy-Clips, 300€ for an Endostapler as well as 20€ for two endoloops. When using those, it needs to be kept in mind, that the operation time with endoloops is expected to be longer. This has a corresponding impact to process costs.
- Complication rates for intra-abdominal and superficial surgical site infections are comparable with other methods of appendix stump closure.

DS APPENDECTOMY-CLIP

CLINICAL USE

ABSTRACT

APPENDIX STUMP CLOSURE WITH TITANIUM CLIPS IN LAPAROSCOPIC APPENDECTOMY.

Rickert A, Bönninghoff R, Post S, Walz M, Runkel N and Kienle P

Langenbecks Arch Surg. 2012 Feb; 397(2): 327–331.

PURPOSE:

Different techniques, including clips, have been used to close the stump in laparoscopic appendectomy. The aim was to investigate the results after application of a newly developed titanium clip for this operation.

METHODS:

From June 2008 to February 2010, 104 patients from two different hospitals undergoing laparoscopic appendectomy were included in this prospective study. Closure of the appendix base was generally intended with a titanium double-shanked clip (DS-Clip). The variables of interest were intra- and postoperative complications, operation time and hospital stay. Furthermore, an evaluation of the clip's practicability by the surgeon was performed using a standardised questionnaire.

RESULTS:

In 104 patients screened intraoperatively, four patients had to be excluded as the operating surgeon felt that the clip was not adequate for closing the stump, generally because of severe inflammation of the base of the appendix with involvement of the caecum. One patient developed an intra-abdominal abscess which had to be drained interventionally; no reoperations were necessary. The overall complication rate, the operation time and the hospital stay were well comparable with other devices for appendix stump closure such as staplers, loops or polymeric clips. The practicability of the clip was mainly rated as excellent or good by the operating surgeons.

CONCLUSION:

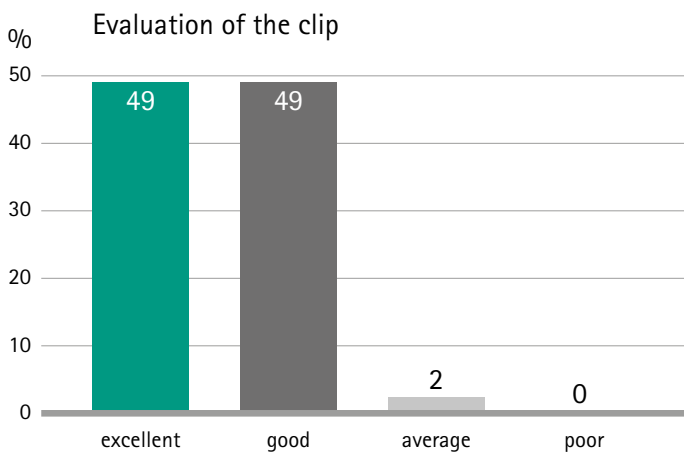
This study suggests that the presented titanium DS-Clip is a safe and cost-effective technique for securing the appendix base in laparoscopic appendectomy. The application is easy and can be learned quickly, making it a good option also for teaching hospitals.



← <https://www.ncbi.nlm.nih.gov/pmc/articles/PMC3261406>

MAJOR STATEMENTS

- Appendectomies are the most frequent emergency operation and it is referenced that there is equality of usage, comparing laparoscopic and open appendectomies.
- The vast majority of surgeons judged the DS Appendectomy-Clip with excellent or good regarding fitting of the clip, view on the applicator and clip, handling of the applicator and the clip and overall rating of the clip. Their usage is simple and fast to learn.



- The clip application of the DS Appendectomy-Clip is easy to learn. Based on the closing mechanism of the clip, the risk of pushing tissue out of the clip is reduced.



- Appendix stumps with a diameter as wide as 20 mm could be closed in a safe way and one clip on each side was generally ample.
- One major conclusion is, that the usage of clips can considerably reduce costs in comparison to linear staplers.
- The operation time, the overall complication rate, and the hospital stay were comparable to other devices for appendix stump closure, like linear staplers or endoloops.

DS APPENDECTOMY-CLIP

CLINICAL USE

Translated from:
Expert Script C99001,
published by Aesculap AG

APPENDECTOMIES - INDICATIONS AND A COMPARISON OF THE VARIOUS TREATMENT METHODS.

Eisenberger CF, Wasmuth D

By order of Aesculap AG, taken from Expert Script C99001, published by Aesculap AG

INTRODUCTION:

The Cologne-Holweide clinic of *Kliniken der Stadt Köln gGmbH* is a sophisticated basic and standard care hospital with focus spectrum oncology center, thyroid and parathyroid center and intestine center. The surgical department has 108 beds and performs approximately 4,200 operations per year. The clinic for general, visceral and trauma surgery has a head of department, five senior physicians and 18 medical assistants.

The department provides the full range of general, visceral and trauma surgery, with the exception of organ transplants. This includes, in particular, esophageal and gastric surgery, intestinal surgery (certified German Hospital Federation [DKG] intestine center), hepatobiliary surgery (oncology center), pancreatic surgery (oncology center), endocrine surgery (German Association of Endocrine Surgeons [CAEK] and German Society for General and Visceral Surgery [DGAV] certified center of excellence for thyroid gland and parathyroid gland surgery, member of the NET Register for the treatment of neuro-endocrine tumors), hernia surgery as well as surgical intensive medicine.

At the clinic in 2011 n=72, in 2012 n=88 and in 2013 n=93 appendectomies were performed, of which over 98% were performed laparoscopically.



Fig. 1 Patient after conventional appendectomy

APPENDECTOMY:

The appendectomy is the most frequently performed operation in general and visceral surgery worldwide.

In Germany, more than 130,000 of these operations are performed every year.

In 1735 the French surgeon Claudius Aymand performed the first successful appendix operation. The diagnosis of "acute appendicitis" is generally made clinically. In addition to the patient's case history and the clinical examinations, there are various laboratory tests and imaging procedures (sonography, computed tomography) that confirm a suspected diagnosis. Operating techniques have improved continuously over the years. Until the mid 1990s an open appendectomy via a McBurney's incision in the lower right abdomen was the standard procedure.

Since then, minimally invasive surgery has largely replaced open surgery as the standard. Today, more than half of these operations are ended laparoscopically¹. Variables, such as less post-operative pain, lower numbers of wound infections, quicker postoperative recovery and shorter hospitalization periods are the benefits of the laparoscopic technique. In addition to the longer operating time, a slightly increased occurrence of intra-abdominal abscesses and higher costs compared to open procedures could be described as disadvantages^{2,3,4}. Several studies and a systematic Cochrane Collaboration review have shown that laparoscopic appendectomy is at least equal to the open removal of the appendix^{5,6}.

During a laparoscopic appendectomy, the base of the appendix is ligated with one or more endoloop ligatures, using a surgical stapler (so-called Stapler or Endo-GIA) or with non-absorbable clips. Once the pneumoperitoneum has been induced, generally 3 trocars are placed in the abdominal wall: the optical trocar in the umbilical region, and optionally a working trocar above the symphysis or in the lower right abdomen and another working trocar in the lower left abdomen. The patient, who is in a supine position, is positioned in head-down position and in the left lateral position so that the intestine is moved in a cranial direction. This exposes the cecal region, the vermiform appendix is then skeletonized. The appendicular artery is usually clipped with titanium clips, following adhesiolysis of the base of the appendix, this is closed using one of the above techniques and the vermiform appendix is removed. The appendix is then removed via a trocar or in a specimen retrieval bag. After peritoneal lavage, the pneumoperitoneum is drained, the fascial incision closed and the operation ended with the skin suture. The insertion of a drainage seems to be optional and is at the discretion of the surgeon in conjunction with the intraoperative findings. There is no evidence-based data that shows that inserting a drainage provides an advantage.

DS APPENDECTOMY-CLIP

CLINICAL USE

COMPARISON OF THE RESPECTIVE TECHNIQUES:

The appendectomy is a routine operation in surgical medicine, and the laparoscopic minimally invasive procedure, in particular, has established itself as a standard procedure.

The use of comparable materials (double-shank titanium clip, stapler, Roeder loop) has already been tested by the respective manufacturers. They are subject to the German medical devices act and have a CE certificate.

These tests have shown that using a stapler is currently the safest method to secure the base of the appendix. However, it is also the most expensive method⁷. As an alternative, the use non-absorbable plastic clips to close the appendiceal stump has been investigated in recent years^{8,9}. It was shown that the use of these clips is safe, cost-effective and at the same time easy to learn. Delibegovic et al. carried out a randomized prospective study in 2012 that compared the use of endoloop, endo-GIA and plastic clips for securing the appendix against one another. This provided statistically significant evidence that plastic clips could be used safely, simply and cost-effectively.

As a disadvantage, the limited availability of different clip sizes with regard to the plastic clips was mentioned¹⁰. Using double shank appendectomy clips, large appendiceal bases can also be securely closed due to their clip length, which is comparatively high. In a feasibility study recently carried out, double-shank titanium clips were used to close the appendiceal stump. It was shown that the use of these clips is safe, cost-effective and at the same time easy to learn¹¹. There are currently no prospective, randomized data available for this comparison. By using a Roeder loop (Prolene respectively PDS, Ethicon) to close the appendix base, another Roeder loop was positioned distally from the first loop around the appendix, the appendix was removed, using a scissors to cut between the two loops. A similar approach was taken for securing the base of the appendix with non-absorbable clips (Hem-o-lok, DS Appendectomy-Clips); instead of the Roeder loops, the appendix was removed, cutting between two identical clips. Removing the vermiform appendix using a stapler is done using a 30 mm cartridge. This staples the lumen and removes the vermiform appendix at the same time. The main advantage of the Roeder loop is the cost aspect (average material costs €11 – €17). Furthermore, in principle, a trocar system with a smaller external diameter can be used so cosmetic aspects come into play. Disadvantages include the sometimes cumbersome handling and the scientifically proven higher incidence of postoperative, intra-abdominal abscesses.

The stapler is easier to use, is a safer system and can be used quickly. In addition, it can also be used for larger organ diameters at the base of the appendix. The costs of the stapler system must certainly be seen as a disadvantage. A 12.5 mm working trocar is also required to insert the device due to its design.

The non-absorbable clip system provides a compromise with regard to the cost aspect, it is still easier to use and the handling is very easy to learn. Due to its design, a 12.5 mm working trocar must currently be used, which makes it necessary to insert another fascial suture in the lower abdomen around the trocar, as otherwise there would be a danger of a trocar hernia. The use of a trocar system with a larger external diameter must also be considered from an aesthetic perspective. In this regard, the use of a 10 and 12 mm trocar system is a disadvantage. Using a single port system could be a way out of this; however, it cannot be used in every physical constitution.

Overall, patients are generally well cared for by all the three methods described. There are no major differences between the systems. Therefore the cost aspects of the systems are increasingly coming into focus.

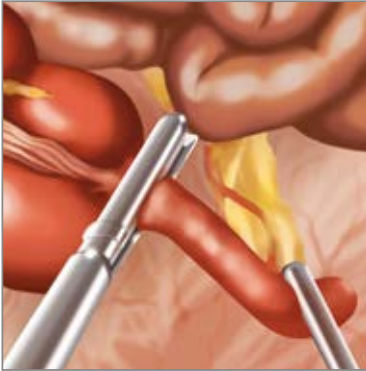

Fig. 2 Removing the appendix using a stapler

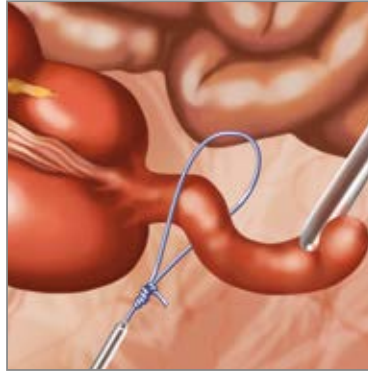

Fig 3. Removing the appendix using a Roeder loop

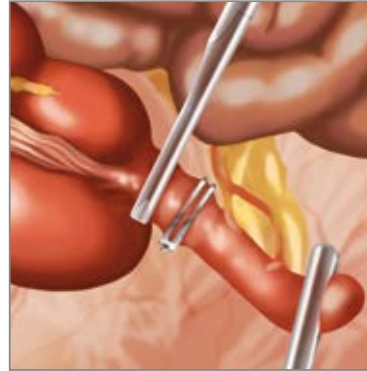

Fig. 4 Removing the appendix using a DS Appendectomy-Clip

EXPERIENCE IN RECENT YEARS:

At the Cologne-Holweide Clinic's clinic for general, visceral and trauma surgery, appendectomies are primarily performed laparoscopically, with all 3 techniques used, but predominantly appendectomies using non-absorbable clips and staplers. Appendixes with a maximum diameter of up to 12 mm are mainly treated with the DS Appendectomy-Clips, larger appendixes are removed with the stapler. If there are any doubts or unclear findings, the appendix is removed using a stapler. To compare the size, the size of the organ is compared with the size a laparoscopic instrument (e.g. Maryland dissector).

CONCLUSION:

From our experience it can be concluded that the use of the DS Appendectomy-Clips is easy to learn and handle, particularly for young colleagues. Compared to the loop, the clip offers higher quality and is less expensive than the stapler system. A reduction in the size of the clip applicator, if technically feasible, would be desirable. A clip applicator for 5 mm or 10 mm trocars would be an aesthetic and functional improvement, as the incidence of trocar site hernias - which potentially occur more frequently with the use of a 12 mm working trocar - could be reduced. 10 mm trocars are however also needed in general, to remove the appendix after it has been displaced.

DS APPENDECTOMY-CLIP

CLINICAL USE

REFERENCES / SOURCE INFORMATION

- 1 Eypasch E, Sauerland S, Lefering R, Neugebauer EA. Laparoscopic versus open appendectomy: between evidence and common sense. *Dig Surg.* 2002;19(6):518-22.
- 2 Krisher SL, Browne A, Dibbins A, Tkacz N, Curci M. Intra-abdominal abscess after laparoscopic appendectomy for perforated appendicitis. *Arch Surg.* 2001 Apr;136(4):438-41.
- 3 Sporn E, Petroski GF, Mancini GJ, Astudillo JA, Miedema BW, Thaler K. Laparoscopic appendectomy - is it worth the cost? Trend analysis in the US from 2000 to 2005. *J Am Coll Surg.* 2009 Feb;208(2):179-85.e2.
- 4 Köckerling F, Schug-Pass C, Grund S. Laparoscopic appendectomy. The new standard? *Chirurg.* 2009 Jul;80(7):594-601.
- 5 Sauerland S, Jaschinski T, Neugebauer EA. Laparoscopic versus open surgery for suspected appendicitis. *Cochrane Database Syst Rev.* 2010 Oct 6;(10):CD001546.
- 6 Gorenai V, Dintsios CM, Schönermark MP, Hagen A. Laparoscopic vs. open appendectomy: systematic review of medical efficacy and health economic analysis. *GMS Health Technol Assess.* 2007 Jan 29;2:Doc22.
- 7 Kazemier G, in t Hof KH, Saad S, Bonjer HJ, Sauerland S. Securing the appendiceal stump in laparoscopic appendectomy: evidence for routine stapling? *Surg Endosc.* 2006 Sep;20(9):1473-6. Epub 2006 Jul 3.
- 8 Hanssen A, Plotnikov S, Dubois R. Laparoscopic appendectomy using a polymeric clip to close the appendicular stump. *JSL.* 2007 Jan-Mar;11(1):59-62.
- 9 Delibegovic S, Matovic E. Hem-o-lok plastic clips in securing of the base of the appendix during laparoscopic appendectomy. *Surg Endosc.* 2009 Dec;23(12):2851-4.
- 10 Delibegovic S. The use of a single Hem-o-lok clip in securing the base of the appendix during laparoscopic appendectomy. *J Laparoendosc Adv Surg Tech A.* 2012 Jan-Feb;22(1):85-7.
- 11 Rickert A, Bönninghoff R, Post S, Walz M, Runkel N, Kienle P. Appendix stump closure with titanium clips in laparoscopic appendectomy. *Langenbecks Arch Surg.* 2012 Feb;397(2):327-31.

- The different considered methods (clips, stapler, Roeder loop) do not have fundamental clinical differences, leading the focus to cost aspects
- The usage of the DS Appendectomy-Clip is stated as safe and easy to learn, while offering simultaneously price savings in comparison to staplers.

MAJOR STATEMENTS

DS APPENDECTOMY-CLIP PERFORMANCE

Translated from:
Passion Chirurgie, 2013

MANAGING THE APPENDICULAR STUMP DURING A LAPAROSCOPIC APPENDECTOMY.

Partecke LI, Dietrich S

Partecke L.I, Diedrich S, Die Appendixstumpfvorsorgung bei der laparoskopischen Appendektomie. Passion Chirurgie. 2013 April; 3(04): Artikel 03_01.

The appendectomy continues to be the most common emergency operation in general and visceral surgery. The conservative antibiotic treatment touted by some working groups in recent years does not represent a serious alternative to surgical intervention. Even though studies have shown that cases of uncomplicated appendicitis do not necessarily require surgery in the middle of the night, and that delaying the operation slightly does not increase morbidity, all surgical clinics must have trained physicians on staff who can provide high-quality surgical therapy for acute appendicitis at any time of the day or night.

This is why continuing education for surgeons in appendectomy techniques is so highly valued. In 1894, McBurney pioneered McBurney's incision on the right side of the lower abdomen. This form of open surgical incision shaped the operative techniques of generations of surgeons. It was performed safely in a highly standardized way. In the early 1980s, Kurt Semm, a gynecologist from Kiel, Germany, performed the first laparoscopic appendectomy (LA). Semm was already aware that the crucial component of LA was the safe management of the appendicular stump.

Only when this is successful can LA compete with the open procedure and its advantages be realized. Similar to the open procedure, Semm closed the base of the appendix with a Roeder loop followed by a purse-string suture and Z-suture in his first description of his laparoscopic technique. This procedure constituted the standard approach to LA in many clinics for a number of years.

The main factors behind the slow adoption of LA as a standard procedure were primarily intra-abdominal abscesses that were frequently described in early years, as well as significantly higher costs compared to the open procedure. In addition, LA had to compete with the high degree of standardization and low rates of complication associated with the open appendectomy technique. Moreover, the laparoscopic technique that Semm described was very challenging for surgeons who had less experience with laparoscopy. With the introduction of linear staplers in laparoscopic surgery and more and more surgeons with better and better training in laparoscopic surgical techniques, LA gained broader acceptance in Germany as well and can now be considered the standard approach even in cases of advanced appendicitis.

As mentioned above, the decisive step in LA is the safe closure of the base of the appendix. The most commonly used techniques that are used to provide safe, easy, highly-standardized care that is as cost-effective as possible are:

- the endoloop (made of PDS® or Vicryl®),
- the clip (non-absorbable polymer clip or titanium clip),
- and the endostapler.

THE ENDOSTAPLER:

The main advantage of the endostapler is that it is fast and easy to use, thanks to its ability to seal and transect tissue in a single step. It also offers the possibility of tangentially resectioning the wall of the cecum. It is simple to use on an appendix with minimal inflammatory alterations. However, managing the base of the appendix in cases of advanced appendicitis requires extensive experience. The main disadvantage of the endostapler is its high price. Therefore it should only be used if the infection extends to the base of the appendix or if the base of the appendix has thickened considerably.

Thus there is a clear indication for the use of the endostapler: advanced appendicitis that extends to the base of the appendix.

THE ENDOLOOP:

Semm used endoloops (Roeder loops) during his earliest applications of LA. They are either made of Vicryl® or PDS® and are used primarily in cases of uncomplicated appendicitis. The correct placement of the loop requires laparoscopic skill, meaning there is a certain learning curve involved. The technique itself is simple: the appendix can be resected between an endoloop placed near the base and one placed more distally. The loop is also a good option in cases of a thicker appendix base.

The sinking of the appendix stump was always a frequent topic of discussion. In the early years of LA, sinking the appendix stump was claimed. In the meantime, several prospective studies have shown that it is safe to manage the stump using a single, unsunken PDS® or Vicryl® loop. Managing the stump with two loops is not safer; but instead increases the risk of developing gangrene on the stump.

The cost of endoloops is comparatively low. In addition, surgeons can make their own knots for distal management, thereby reducing costs further.

THE CLIP:

To date, two different clip systems have been used in LAs: The polymer Hem-o-lok clip (Hem-o-lok MLX polymeric clip, Weck Closure Systems, USA) and the titanium clip (DS-Clip, Aesculap, Germany). Both clips have a closing mechanism on the distal ends and therefore remain securely in place following application (Figure 1 A-D).

They are significantly easier to use than endoloops, particularly when it comes to placing them correctly on the base of the appendix. It is easy for young surgeons to learn how to use them. Their use resembles the management of the cystic duct during a laparoscopic cholecystectomy, for example.

The disadvantage of clips is that they can only ensure safe closure for a limited range of appendix diameters. This is approximately 16 mm for the Hem-o-lok clip and approximately 20 mm for the DS-Clip. For both clips, placing only one clip at the base is sufficiently safe. In a study designed to evaluate use of the titanium DS-Clip during an LA, Rickert et al.* asked the practicing surgeons how they would assess the fit of the clip, handling during application, and visibility during application. In all categories, the DS-Clip was predominantly rated "excellent" or "good". 41 percent of the basic assessments rated the clip as "excellent" and another 41 percent rated it as "good". Only 2 percent of the assessments rated it as "average." The study is obviously somewhat biased. However, it does show that the clips are very easy to use during a laparoscopic appendectomy. The price for

DS APPENDECTOMY-CLIP PERFORMANCE

five Hem-o-lok clips is about € 19 and about € 80 for four titanium DS-Clips, meaning that we can assume that clips will be used to manage the appendix base in the future, at least in cases of uncomplicated appendicitis. At the moment, the Hem-o-lok clip is significantly less expensive, whereas the titanium DS clip can manage a broader appendix base.

Neither system offers a true advantage over the other, however, meaning that the choice of system will depend on the personal preferences of the individual surgeon or surgical clinic.

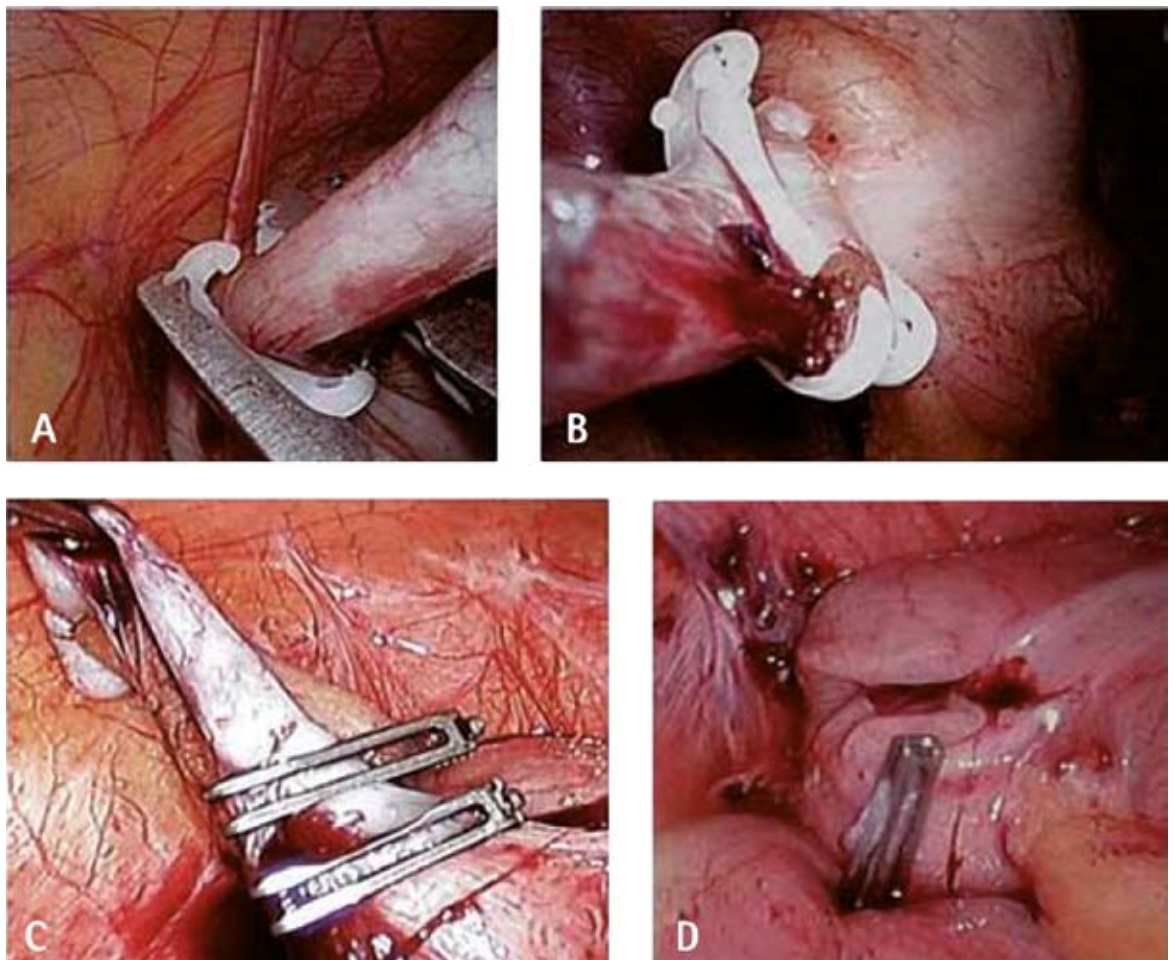


Fig. 1:

- A: Hem-o-lok clip: Application of the clip at the base of the appendix. The distal closing mechanism can easily be seen;
- B: Hem-o-lok clip: Situation following management with both a distal and proximal clip prior to resecting the appendix between the two clips;
- C: Titanium DS-Clip: Two clips have been applied - situation prior to resecting with scissors. The distal closure can easily be seen here as well;
- D: Titanium DS-Clip: Situation following the removal of the appendix - one clip at the appendix base ensures safe closure.

Procedure	Advantages	Disadvantages
Endoloop	<ul style="list-style-type: none"> can be used in most cases safe in cases of mild inflammation use does not depend on the diameter of the appendix cost-effective 	<ul style="list-style-type: none"> high level of training required exposed mucosa on the appendix stump longer appendix stump primary management of the appendix base with subsequent retrograde dissection of the mesoappendix is not possible
Clip	<ul style="list-style-type: none"> easy to use minimal mucosa remaining on the appendicular stump primary closure and removal of the appendicular base and subsequent retrograde mobilization of the appendix possible cost-effective more clips can be used to manage the mesoappendix and the appendicular artery 	<ul style="list-style-type: none"> the diameter of the appendix base is limited to 16-20 mm may not provide enough safety if the appendix base is inflamed. non-absorbable
Stapler	<ul style="list-style-type: none"> safer closure of the appendix base, even when the appendix base is inflamed possibility of partial cecum wall resection no mucosa remaining on the appendicular stump easy to use stapler can be closed and appendix can be resected in a single step primary management of the appendix base and subsequent retrograde dissection of the mesoappendix is possible 	<ul style="list-style-type: none"> Possible malfunctions: cutting without stapling, stapling without cutting, incomplete closure of the staples, loss of the staples staples not absorbable expensive

Tab. 1: Comparison of the advantages and disadvantages of the three techniques of appendix base closure in laparoscopic appendectomies (adapted from and used with permission from the Georg Thieme Verlag)

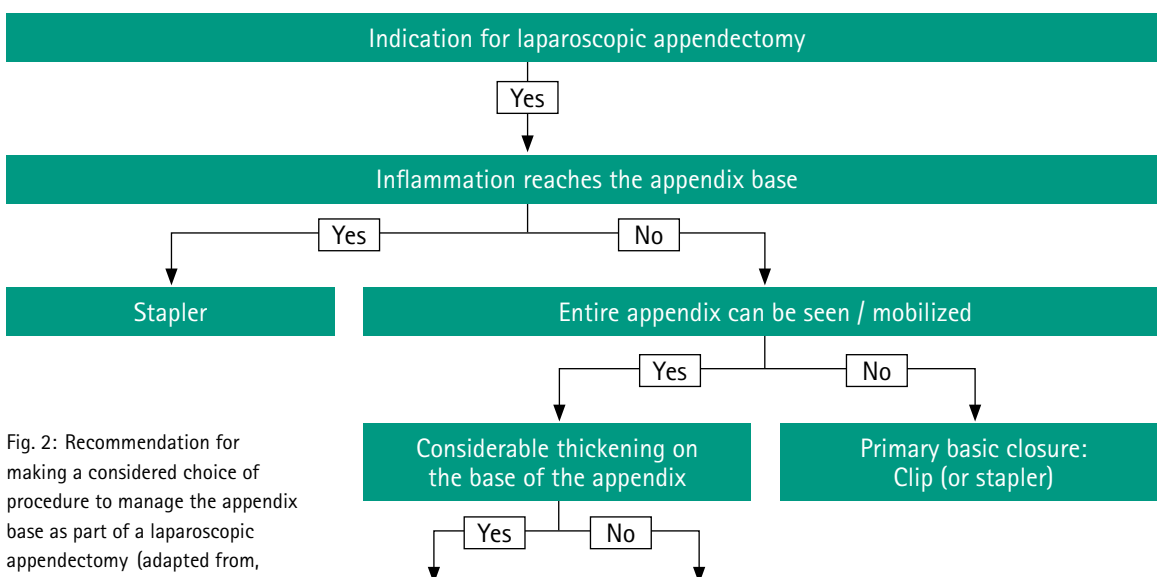


Fig. 2: Recommendation for making a considered choice of procedure to manage the appendix base as part of a laparoscopic appendectomy (adapted from, used with permission from the Georg Thieme Verlag)

DS APPENDECTOMY-CLIP PERFORMANCE

CONCLUSION:

The advantages and disadvantages of the three methods of managing the appendix base during an LA (endostapler, endoloop, and clip) are summarized in Table 1. The available data from the literature and the specific features of the three competing methods suggest the following recommendation for the standardized management of the appendix base during an LA, depending on the local infection situation.

In the vast majority of cases of uncomplicated phlegmonous appendicitis, the appendix base can be safely managed with a single clip at the base. Each clinic should decide on one of the two clip systems in order to minimize morbidity during routine use. Due to its ease of use, the clip could become the standard approach for uncomplicated appendicitis in the future. For complicated diagnostic findings of advanced appendicitis that also includes the appendix base, the stapler is indicated.

MAJOR STATEMENTS

- Laparoscopic appendectomies can be considered as standard approach even for advanced appendicitis.
- For appendectomies, clips are significantly easier to use in comparison to endoloops and are comparatively well known from other indications, such as cholecystectomies.
- Among others, the choice of the treatment method is influenced by the inflammatory status of the appendix as well as the surgeon's preference.
- In summary, for uncomplicated appendicitis, clips are described as potential standard method in the future.

AESCULAP[®] – a B. Braun brand

Aesculap AG | Am Aesculap-Platz | 78532 Tuttlingen | Germany
Phone +49 7461 95-0 | Fax +49 7461 95-2600 | www.aesculap.com

The main product trademark 'Aesculap' and the product trademark 'Challenger' are registered trademarks of Aesculap AG.

Subject to technical changes. All rights reserved. This brochure may only be used for the exclusive purpose of obtaining information about our products. Reproduction in any form partial or otherwise is not permitted.